Check for updates

Stroke: Vascular and Interventional Neurology

REVIEW

Mastering the Maze: A Narrative Guide on Advanced Tips and Tricks for the Management of Complex Thrombectomy

Benjamin Maïer, MD, PhD*; Solène Hébert, MD*; Simon Escalard, MD; Hocine Redjem, MD; Jean-Philippe Desilles, MD, PhD; William Boisseau, MD, MSc; Erwan Robichon, MD; Amira Al Raaisi, MD; Samuel J. Mouyal, MD, MSc; Arthur Gutter, MD; François Delvoye, MD, PhD; Stanislas Smajda, MD; Raphaël Blanc, MD, MSc†; Michel Piotin, MD, PhD†; Mikael Mazighi, MD, PhD†

ABSTRACT: Endovascular therapy has revolutionized the treatment of acute ischemic stroke with large vessel occlusion, becoming the standard of care across anterior and posterior circulation. With expanding indications, including large infarct cores, extended time windows, and older patients, the number and complexity of procedures are steadily increasing worldwide. Although overall rates of successful reperfusion approach 90%, the remaining 10% of failed endovascular therapy highlight the technical challenges still confronting interventionalists. Procedural failure may occur at multiple stages, from arterial puncture to supra-aortic catheterization, intracranial navigation, or closure, each requiring tailored strategies. This review gathers advanced tips and tricks to manage demanding situations, reflecting both published evidence and the long-standing oral transmission that often occurs during fellowships. Practical solutions are described for frequent challenges, including complex femoral access and closure, tortuous supra-aortic vessels, difficult carotid siphons, and hostile intracranial anatomy. Techniques such as buddy-wire, balloon anchoring, stent-anchoring, balloon tracking, direct carotid puncture, and the flossing technique are detailed, alongside structured escalation strategies. Beyond technical skills, this review emphasizes the importance of comprehensive training. Mastery of complex diagnostic cerebral angiographies, supported by simulation-based learning, is considered more relevant than procedural counts to determine readiness for on-call independence. Ultimately, competence is defined not by the number of endovascular therapies performed, but by the ability to anticipate and safely manage complications in unpredictable anatomic settings. Future training should integrate procedural volume, case complexity, and simulation to prepare the next generation of interventionalists to perform endovascular therapy and navigate the unexpected with safety and confidence.

Key Words: catheters ■ endovascular procedures ■ ischemic stroke ■ stents ■ thrombectomy

Downloaded from http://ahajournals.org by on March 15, 2026

Endovascular therapy (EVT) has become the standard of care for acute ischemic stroke caused by both anterior and posterior large vessel occlusions.[1,2] In the anterior circulation, EVT has consistently demonstrated superiority over best medical management, and similar benefits have been confirmed for posterior large vessel occlusion.[1,2] Since the landmark randomized trials in 2015, the indications for EVT have expanded steadily. To date, EVT is recommended even in patients with large (Alberta Stroke Program Early Computed Tomography Score 3–5) and extremely large ischemic core (Alberta Stroke Program Early Computed Tomography Score 0–5),[3–8] within 24 hours of last seen well,[9] with easier and more straightforward neuroimaging protocols for selection (ie, no perfusion),[10] allowing the selection of patients from any emergency or neurology department

Correspondence to: Benjamin Maïer, MD, PhD, Interventional Neuroradiology Department, Hôpital Fondation A. de Rothschild, 25-29 rue Manin, 75019, Paris, France. Email benjamin.maier025@gmail.com
*B. Maïer and S. Hébert contributed equally.
†R. Blanc, M. Piotin, and M. Mazighi contributed equally.
© 2026 The Authors. *Stroke: Vascular and Interventional Neurology* is published on behalf of the American Heart Association, Inc. and the Society for Vascular and Interventional Neurology by Wolters Kluwer Health, Inc. This is an open access article distributed under the terms of the Creative Commons Attribution Non-Commercial License 4.0, which permits use, distribution, and reproduction in any medium, provided that the original work is properly cited, the use is noncommercial.
Stroke: Vascular and Interventional Neurology is available at www.ahajournals.org/journal/svin

Nonstandard Abbreviations and Acronyms

ACA	anterior cerebral artery
AIS	acute ischemic stroke
BGC	balloon guide catheter
DMVO	distal-medium vessel occlusion
ECA	external carotid artery
EVT	endovascular therapy
ICA	internal carotid artery
INR	interventional neuroradiology
LVO	large vessel occlusion
MCA	middle cerebral artery

where advanced neuroimaging modalities are not available. In addition, several post hoc analyses of randomized trials and observational studies have also suggested the beneficial effect of EVT for anterior large vessel occlusion in patients presenting with baseline disability (modified Rankin Scale score ≥2), >80 or 90 years old, altogether significantly increasing the number of eligible patients for EVT.[11,12] These last few years of EVT implementation, together with the results of the major randomized trials, have taught us several key insights. First, achieving successful reperfusion (modified Thrombolysis in Cerebral Infarction 2b-3) remains the ultimate goal, as outcomes after failed EVT mirror those of patients managed medically in early trials.[1] Moreover, the quality of reperfusion matters in successfully treated patients, as patients with a final modified Thrombolysis in Cerebral Infarction 2c-3 have better outcomes than patients with modified Thrombolysis in Cerebral Infarction 2b reperfusion.[13] That being said, despite steady progress worldwide in the proportion of successful EVT (now reaching 90%),[14] EVT procedures tend to become more aggressive for the 10% of patients without successful reperfusion. These cases are an interesting topic of research in several respects. First, these procedures typically demand more advanced technical skills than easy EVT procedures (ie, first-pass effect) and require a much more advanced expertise. Second, failure may occur at different stages of the EVT procedure (arterial puncture, supra-aortic vessels catheterization, intracranial procedure, arterial closure), each stage requiring dedicated solutions. Given the increasing number of EVTs performed worldwide and the broader, often more complex patient profiles (older age, larger strokes), such technically demanding situations are expected to become more frequent.[15]

Although prior studies have described selected technical challenges encountered during endovascular procedures (during EVT or aneurysm embolization), a comprehensive and practical synthesis aimed at young interventionalists is still lacking.[16–18] The aim of this narrative review is, therefore, to translate the long-lasting oral tradition of tips and tricks into a written and illustrated guide, structured by stage of the procedure to deal with complex EVT. Most of these techniques are usually discussed, learned, or put into practice during neuroendovascular fellowships, and we think formalizing them can help fellows and junior staff acquire higher-level skills more quickly. This review does not cover the different techniques of reperfusion (eg, BADDASS [Balloon Guide With Large Bore Distal Access Catheter With Dual Aspiration With Stent-Retriever as Standard Approach] or SAVE [Stent Retriever Assisted Vacuum-Locked Extraction]), for which excellent reviews already exist.[19] Rather, it focuses on technical pitfalls and bailout strategies. Readers should be aware that these tips and tricks and techniques do not stem from randomized controlled trials, but from decades of collective experience, some of it accumulated over 30 years and countless hours spent in the cath-lab.

ARTERIAL PUNCTURE: 7 MINUTES EVT BUT 90 MINUTES COMPRESSION

Every senior interventional neuroradiology (INR) has faced the paradox of an ultrafast and technically flawless EVT procedure, only to be slowed down by a problematic femoral puncture closure, ending with more than an hour of manual compression, sometimes ironically nicknamed Fellowseal. Groin puncture complications are particularly frequent in our field due to the large sheath sizes required (8F–9F), the underlying arterial disease (atherosclerosis), and concurrent treatments (intravenous thrombolysis, anticoagulation, antiplatelet therapy).[20] This risk may increase further as ongoing randomized trials explore the adjunctive use of potent antiplatelet and fibrinolytic agents during EVT (anti-P2Y12, anti-GP [glycoprotein] VI, anti-GP2b3a, intra-arterial fibrinolysis), thereby putting a risk of groin hemorrhagic complications, similar to interventional cardiology. Among the modifiable and actionable targets to prevent this complication are (1) the choice of arterial access and (2) the puncture technique.[20] Although radial access has become standard in coronary interventions, its role in acute ischemic stroke remains debated. Some data suggest that radial access prolongs supra-aortic navigation during EVT, whereas a small randomized trial found noninferiority compared with femoral access.[21,22] Yet, radial access for EVT limits the use of large-bore devices: 9F balloon guide catheters are not an option, as well as large-bore aspiration catheters (0.88″), and the availability of 7F or 8F balloon catheters for radial access is limited worldwide. That said, we strongly think that puncture technique matters as much as access choice, even in the time-critical context of stroke. Fellows should make ultrasound-guided puncture their default (mandatory for radial access, highly recommended for femoral access, especially in

Downloaded from http://ahajournals.org by on March 15, 2026

older patients), to precisely pinpoint the common femoral artery, femoral bifurcation, as well as small perforating branches at risk of bleeding. In our experience, the 2 minutes lost at puncture are often regained later by preventing complications that can turn a smooth EVT into a nightmare. To streamline workflow, we use a dedicated tablet and a wireless ultrasound probe, which are prepared on the sterile table before patient arrival, so puncture can be performed without delay once the patient is in the cath-lab.

SUPRA-AORTIC CATHETERIZATION: BREATHE, 90% OF THE WORK IS DONE

As EVT expands to older and more fragile patients, including octogenarians and nonagenarians, the situations of complex or frankly hostile supra-aortic catheterization are becoming more frequent. These situations are associated with worse outcomes at 3 months because of prolonged time from onset to reperfusion and increased rates of embolic complications.[23] Furthermore, this situation can also be mentally draining for the operator. Stress, irritability, and frustration can build up before the intracranial procedure has even started. Many fellows confide that their greatest fear during early independent shifts (nights and weekends) is not the intracranial step, but failing to reach it at all. To manage this stress and avoid postprocedure regret, we encourage fellows to adopt the mindset of highly trained professionals, such as special force operators or fighter pilots, who rely on structured execution strategies (ie, contingency plans) under pressure. In practice, this means predefined steps, escalating in complexity and aggressiveness (Figure 1). Each maneuver is tried for 5 to 10 minutes, then abandoned in favor of the newt if it fails, based on the operator's real-time perception of progress. This structured playbook helps maintain focus, conserve mental energy, and keep the team aligned.

It is worth emphasizing that diagnostic cerebral angiographies are the true training ground for these skills. Often perceived as routine or redundant, they actually provide daily opportunities to practice catheter shaping, torque control, and escalation strategies in a lower-stakes setting. Mastery of these diagnostic drills is what prepares fellows for complex EVT access.

Anticipating EVT Challenges Through Supra-Aortic Imaging

Whenever available, preprocedural imaging of the supra-aortic vessels (computed tomography angiography, magnetic resonance angiography, or high-quality Doppler when relevant) represents a valuable step before EVT. Although its systematic acquisition varies across centers, this assessment can greatly facilitate planning of both vascular access and catheterization strategy. For posterior circulation stroke, meticulous evaluation of vertebral arteries is essential: a right-dominant vertebral artery often favors a radial approach, whereas a left-dominant vertebral artery may be more efficiently reached transfemorally. In an anterior circulation stroke, a radial approach may be preferred in the presence of a bovine-type left common carotid artery or in patients with pronounced aortic arch tortuosity.

Beyond access planning, supra-aortic imaging allows early identification of cervical internal carotid artery (ICA) tortuosity, sus-bulbar or subpetrous loops, and kinking, helping operators anticipate the need for specific techniques (anchoring maneuvers, balloon-assisted advancement, stiffer guidewires). In these highly tortuous proximal anatomies, operators should also be cautious with the use of balloon guide catheters, whose intrinsic stiffness may make navigation more difficult or unsafe. In such settings, softer or nonballoon large-bore guide catheters may provide a more appropriate alternative. Preprocedural supra-aortic imaging can also help anticipate situations in which supra-aortic catheterization is likely to be extremely challenging. In such cases, reviewing the anatomy beforehand allows the operator to consider early the possibility of a direct carotid puncture, when appropriate. This upstream evaluation is particularly useful as it permits (1) a discussion of the indication in light of the patient's overall condition and the location of the primary occlusion, and (2) early coordination with the anesthesia team to optimize procedural safety (especially if general anesthesia, dedicated closure devices, or specific organizational adjustments [cf. infra] may be required). Importantly, this carotid approach may ultimately not be needed if the operator successfully achieves catheterization via the conventional route; however, having anticipated and discussed this option beforehand can significantly accelerate decision-making and streamline management should difficulties arise during the procedure.

Our Primary Setting

Our basecamp approach typically begins with a short 8F or 9F short femoral sheath (depending on whether a balloon guide catheter will be used). Through this, we advance a long 6F sheath over a 5F diagnostic catheter (usually a Simmons 5F Select, Penumbra) and a standard 0.035″ exchange guidewire. This simple setup is our foundation before escalating to more complex maneuvers. Although some teams use long, reinforced introducer sheaths to bypass iliac or aortic loops and improve distal support, this is not part of our routine workflow. In our practice, such sheaths are considered only in very selected situations, most recently when using 8F aspiration catheters intracranially, which may benefit from additional proximal stability during navigation.

Downloaded from http://ahajournals.org by on March 15, 2026

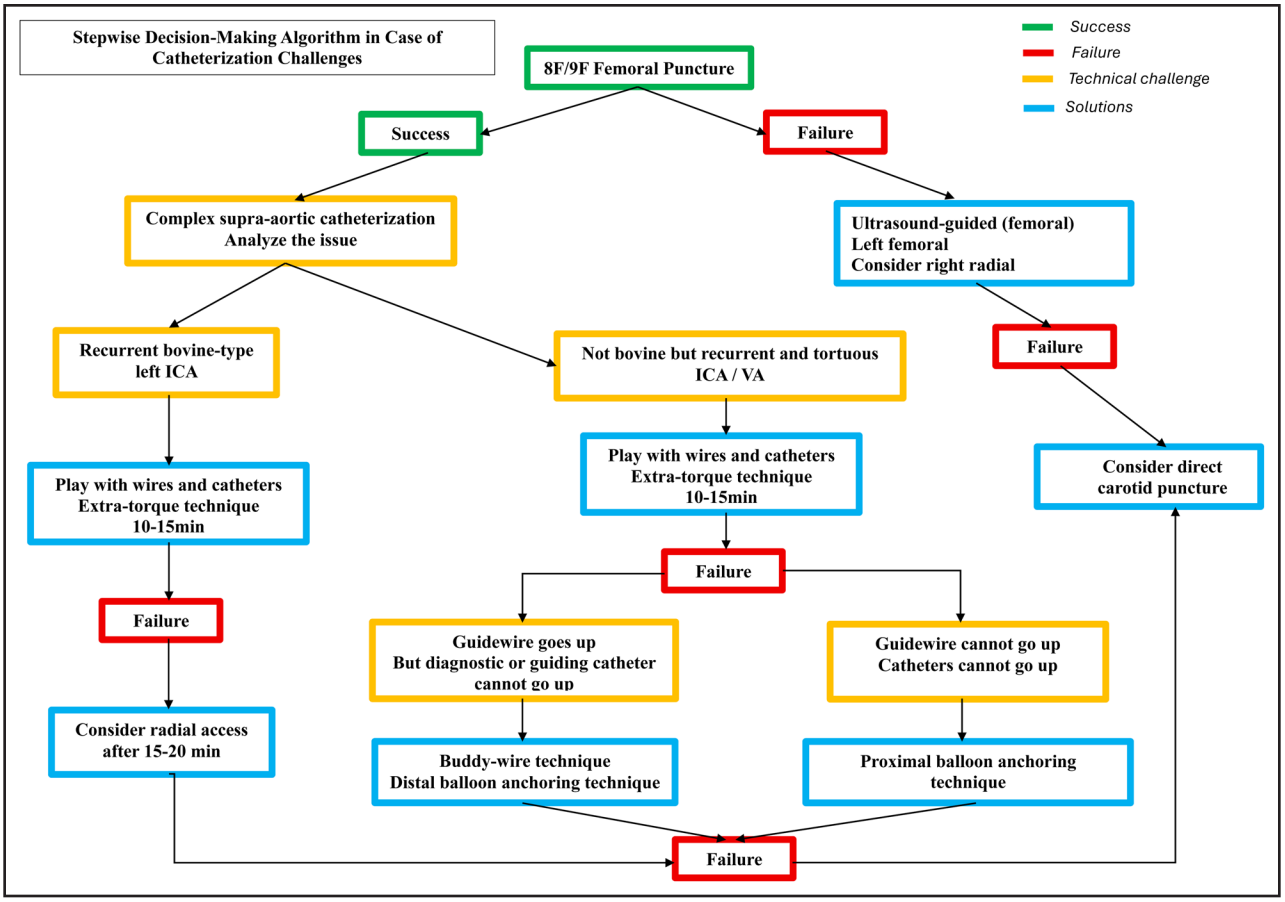

Figure 1. Stepwise decision-making algorithm in case of catheterization challenges.
Main challenges encountered during endovascular therapy (EVT) and proposed solutions according to each specific difficulty. ICA indicates internal carotid artery; and VA, vertebral artery.

Switching to Radial Access

As discussed above, one of the main scenarios where we switch to radial access is a difficult left common carotid artery catheterization in a bovine-type arch. In this setting, the distal tip of the 5F catheter may initially engage the proximal left common carotid artery, but advancing the 0.035-inch wire often causes the catheter to prolapse back into the arch due to proximal tortuosity. From the radial, however, the wire frequently tracks directly into the left common carotid artery, making catheterization easier. Another typical situation is challenging brachiocephalic access with multiple proximal loops, where attempts from femoral access repeatedly result in catheter herniation into the arch. In this case, radial access helps because the wire tends to run preferentially into the right common carotid artery, and retrograde engagement of the brachiocephalic trunk is less cumbersome. For both scenarios, we prefer to switch early to radial rather than losing time with repeated femoral attempts.

Play With the Catheters and Guidewires

When femoral access remains the best strategy and radial is not considered, the next step is to experiment with different catheter-guidewire combinations. In most cases, the diagnostic catheter is introduced inside a long sheath in the aortic arch. This requires catheters of sufficient length (≥100 cm) to maintain stability, which unfortunately excludes many of the 90 cm diagnostic catheters commonly used for complex diagnostic angiographies.

Our first move is often to switch guidewires. If the operator started with a stiff 0.035-inch wire, we usually try a standard one next (and vice versa). Hybrid wires such as the Amplatz Super Stiff (Boston Scientific) or the Glidewire Advantage (Terumo), with a soft distal tip and a rigid proximal shaft, can be particularly useful in tortuous anatomy. For diagnostic catheters, the Simmons, Vertebral (Berenstein), and Headhunter are the most frequently used, with the Headhunter often reserved for brachiocephalic access. Based on the interaction between the wire and catheter, different anchoring maneuvers may be required (see below).

If anchoring is not feasible (eg, no balloon available), another option is to reset the system: withdraw the long sheath, place a short introducer sheath (if not already done), and restart with a 90 cm diagnostic catheter. This allows access to a broader catheter repertoire, though it

Downloaded from http://ahajournals.org by on March 15, 2026

is not an ideal strategy as it consumes time and requires an additional exchange.

Before escalating further, one more trick can be attempted: the so-called extratorque technique. Using a vertebral catheter positioned with the wire in the external carotid artery, the operator applies several progressive counterclockwise rotations with both hands before advancing the catheter. This torque often enables spontaneous advancement through tortuous segments, a classic maneuver in diagnostic angiography.

Additional pearls include playing with the patient's respiration cycle. Under general anesthesia, requesting a brief apnea can straighten the arch and simplify catheterization. This is rarely possible under conscious sedation, as stroke patients are typically nonresponsive.

Finally, in situations where the guidewire advances well into the ICA or external carotid artery but the diagnostic catheter fails to follow, it can be very effective to advance the long guiding sheath itself over the wire. By creating a stable fixed point with the diagnostic catheter at the carotid ostium, the long sheath (eg, NeuronMax, Penumbra, or Ballast, Balt) can sometimes track better through tortuosity thanks to its improved navigation and support properties.

If none of these maneuvers succeed after 10 to 15 minutes, and radial access is not considered easier, it is time to escalate to other strategies based on catheter and wire behavior.

Guidewire Is Up but the Catheter Won't Go Up: Try Buddy-Wire

Sometimes, 2 wires are better than one. The buddy-wire technique provides additional stability, helps navigate tortuous anatomy, and reduces the stair-step or ledge effect often encountered at arterial ostia. Although widely known in intracranial procedures, such as advancing 0.027″ or 0.021″ microcatheters into the anterior cerebral artery for flow diverter delivery,[24,25] the same principle can be applied during challenging supra-aortic catheterizations in EVT.

Several configurations are possible. Within a 5F diagnostic catheter, 2 microwires can be advanced simultaneously. Alternatively, in a 6F catheter, one 0.014-inch microwire can be paired with a 0.035-inch wire. This improves trackability and catheter pushability. Using 2 microwires with J-shaped tips also has the advantage of being relatively atraumatic, allowing them to be advanced further into the ICA or external carotid artery for support. The technique is also particularly useful for difficult vertebral artery catheterizations from femoral access (Figure 2). In this scenario, a stiff 0.035″ wire can be advanced distally into the subclavian and even into the brachial artery to provide proximal support, whereas a second microwire is carefully navigated distally into the vertebral artery.[26] Finally, the buddy-wire technique can also be adapted to intermediate catheters. Modern aspiration catheters with a 0.071″ inner lumen can accommodate one 0.035″ stiff wire alongside a 0.014″ microwire. This may facilitate navigation through highly tortuous segments of the petrous or sub-bulbar ICA. However, in this setting, the technique carries a higher risk of dissection and should be used with caution.

My Catheter Is at the Ostium but Systematically Falls in the Arch: Proximal Anchoring Technique

As described and explained by Sharashidze et al,[16] the proximal balloon anchoring technique is a reliable option when the diagnostic catheter repeatedly prolapses into the arch as the wire is advanced. The principle is straightforward: a balloon guide catheter is positioned just distal to the ostium of the target vessel (eg, the left common carotid). The balloon is then inflated at the ostium, creating a temporary anchor that stabilizes the system and prevents the diagnostic catheter from slipping back into the arch, when the wire is pushed forward. With the balloon inflated, the guidewire and diagnostic catheter can be tracked safely into the external carotid artery. Once this distal position is secured, the balloon guide catheter itself can then be advanced into the ICA. In some cases, the diagnostic catheter can be advanced, but the balloon guide catheter still refuses to track, remaining stuck at the ostium. In this scenario, escalation to the floating (or gliding) balloon technique or distal balloon anchoring techniques (see below) is warranted.

My Diagnostic Catheter or Wire Can Go Up but My Balloon Guide Catheter Cannot Be Tracked and Stay in the Arch: Use Balloon Floating Technique and Distal Balloon Anchoring Technique

When guidewires can be successfully navigated into the external or internal carotid arteries in the anterior circulation, or into the subclavian/vertebral arteries in the posterior circulation, but the catheter (diagnostic, balloon guide, or long sheath) refuses to advance because of tortuosity or arch stiffness, balloon-assisted maneuvers can help.

The balloon floating (or gliding) technique takes advantage of the energy generated by balloon inflation and deflation. With the catheter under slight forward tension, inflation pushes the system upward, and deflation allows it to slide forward. By repeating several cycles of push-inflate-deflate, the balloon guide catheter can progressively gain a few extra centimeters.[27] This maneuver is familiar to operators who have performed coiling with intracranial balloon remodeling, where similar principles are applied. In EVT, the aim is to use the balloon's stored

Downloaded from http://ahajournals.org by on March 15, 2026

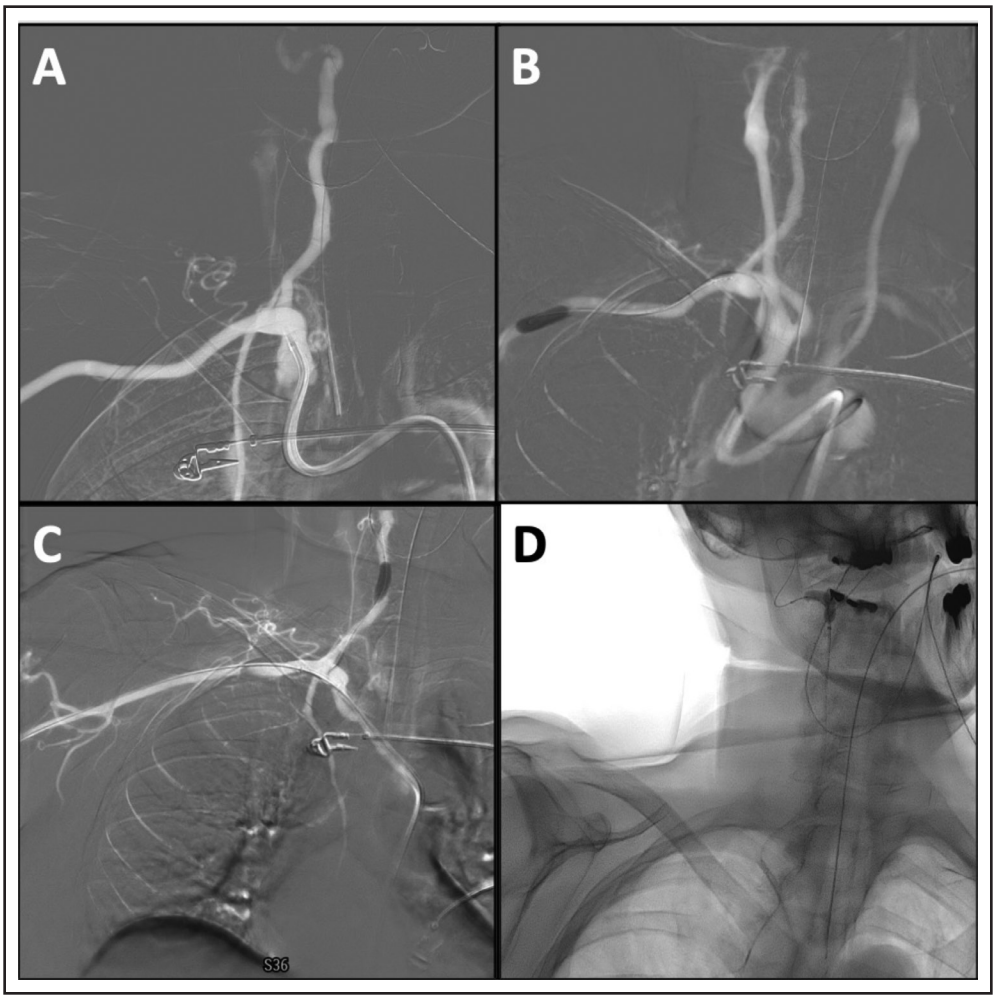

Figure 2. Difficult vertebral artery catheterization using the buddy-wire technique and balloon anchoring technique. **A**, A 5F Headhunter diagnostic catheter (Penumbra) is positioned in the right subclavian artery, with a tortuous brachiocephalic trunk preventing access to the right vertebral artery. **B**, A double-lumen Eclipse balloon (Balt) is advanced over a Synchro 14 microwire (Stryker) into the axillary artery and inflated. With balloon anchoring, a Destination guiding catheter is tracked into the subclavian artery, distal to the vertebral origin. **C**, A 0.035-inch wire is advanced distally into the axillary artery for additional support (buddy-wire technique). The balloon is then reinflated to facilitate microcatheterization of the right vertebral artery and to guide the Destination catheter across the vertebral origin. **D**, The 0.035-inch wire is removed, and the balloon is navigated to the V2–V3 junction and reinflated, allowing the Destination catheter to be advanced further (distal balloon anchoring).

Downloaded from http://ahajournals.org by on March 15, 2026

energy to coax the balloon guide catheter into advancing spontaneously.

The distal balloon anchoring technique is another option when the catheter remains stuck at the ostium. Here, an over-the-wire balloon (extracompliant or compliant, monolumen or dual-lumen) is advanced through the catheter into the petrous ICA, then inflated to provide a distal anchor.[16] This anchoring point stabilizes the system and improves trackability of the catheter across the arch. The same approach can be adapted for subclavian catheterization: the balloon is sequentially inflated in the axillary or humeral artery, and then in the vertebral artery, to pull the long sheath forward (Figure 2). Alternative strategies apply the same principle using a stent retriever for anchoring, with comparable efficacy but higher cost and risk.[28] Regardless of the device, these techniques carry a non-negligible risk of dissection. The operator must maintain continuous control of balloon position on both anteroposterior and lateral views to prevent uncontrolled back-and-forth motion.

Russian Doll Technique: Release Tension and Repush

A difficult maneuver to describe on paper, but absolutely fundamental for managing complex supra-aortic catheterizations. In patients with arterial stiffness, multiple loops, and pronounced tortuosity, advancing a triaxial or quadriaxial system can be challenging. In these situations, success often depends less on pushing harder and more on a subtle touch. This is why, with the exact same setup, a senior operator may succeed where a junior fellow struggles: it is a skill (or art for some) learned through hundreds of hours in the cath-lab, carefully observing how catheters behave under tension.

The key lies in reading the curves of the catheters, which reveal the degree of stored tension in the system (Figure 3). If tension is high and the operator keeps pushing, the entire system will inevitably prolapse. Instead, when tension is observed, it should be released progressively, first on the distal catheter, then on the more proximal ones, before attempting another gentle forward push on the guiding system (Figure 3A and 3B). This push-release-repush sequence, which we call the Russian doll technique, can often make the difference in reaching the intracranial circulation without losing stability. For fellows, this concept may feel paradoxical: counterintuitively, pulling back on the system is sometimes the very maneuver that allows it to advance further. Mastering this apparent contradiction is part of the fine art of catheterization. That said, for longer catheterizations, one additional rule must always be remembered: flush frequently. Neglecting this simple step risks thromboembolic complications that can undo an otherwise perfect maneuver.

I Tried Everything but It Won't Go Up: Let's Get Aggressive

If, after 30 to 40 minutes of attempts, supra-aortic catheterization remains impossible despite all the tricks described above, it is time to escalate to a more aggressive approach. At this stage, the alternative is often to stop the procedure, an option that almost invariably leads to catastrophic outcomes for the patient. The main bailout in this situation is direct carotid artery puncture. Before proceeding, however, the indication must be reassessed carefully, in close collaboration with the neurocritical care team. As highlighted in the CARE study (The Carotid Artery Puncture Evaluation), carotid access carries a significant complication rate, including severe and occasionally fatal complications,[29] and should not be considered in patients with limited expected benefit (eg, a 95-year-old semiautonomous patient with an M2 occlusion and National Institutes of Health Stroke Scale score 6). This multidisciplinary validation is essential to ensure that the risk-benefit balance remains favorable. Whenever feasible, a selective angiogram through the first access should be performed to confirm persistent cervical or intracranial occlusion. In the CARE study, several unnecessary punctures could have been avoided had this verification been performed beforehand.[29] Once carotid access is deemed appropriate, we strongly recommend performing this puncture under general anesthesia, both for patient comfort and to secure the airway in case of cervical hematoma. Puncture can be guided either by a roadmap, using a diagnostic catheter positioned in the arch, or by real-time ultrasound.

As part of the upstream planning, the operator should anticipate the vascular closure strategy before puncture, ensuring the availability of appropriate closure devices (ie, Angio-Seal, Mynx 6) to avoid leaving intraluminal material. In addition, because of the risk of delayed complications such as pseudoaneurysm formation or carotid rupture, we recommend performing a Doppler ultrasound 48 to 72 hours after the procedure.

Taken together, these steps emphasize that carotid puncture is not simply a technical solution but a strategic decision. Its consideration should be integrated early,

Downloaded from http://ahajournals.org by on March 15, 2026

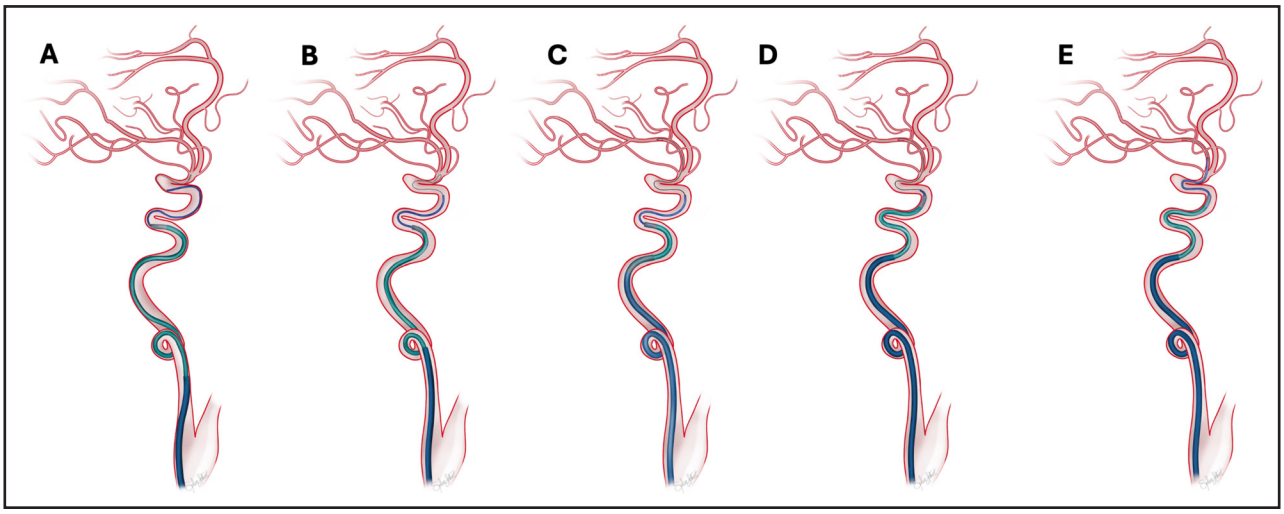

Figure 3. Supra-aortic catheterization using the Russian doll technique.
A, A triaxial system is shown (guiding catheter at the internal carotid artery [ICA] origin, intermediate/aspiration catheter in the petrous ICA, microcatheter in the siphon, and microwire at the middle cerebral artery origin), under marked tension, illustrated by catheter curves bulging against the arterial wall rather than centered within the lumen. This reflects operator push on the catheters within a tortuous anatomy with a sub-bulbar ICA loop. **B**, Release of tension is achieved by pulling back on the system to restore central alignment of the catheters within the vessel. **C**, After tension release, the guiding catheter is advanced while gently pulling on the intermediate catheter, followed by further tension release of the entire system. **D**, The intermediate catheter is then advanced with gentle countertraction on the microcatheter (Russian doll technique). **E**, Finally, the microcatheter and microwire are navigated intracranially, with stability ensured by proper positioning of the guiding and intermediate catheters.

sometimes even before entering the angio suite, based on preprocedural supra-aortic imaging and anticipated catheterization difficulty (cf. supra). Even if this approach ultimately proves unnecessary because transfemoral or transradial access succeeds, having anticipated and prepared for the possibility of carotid access can significantly accelerate the workflow and streamline management should catheterization failure occur.

Finally, although detailed technical descriptions of carotid puncture techniques are available in dedicated reviews,[30] the key point is to recognize when persistence with transfemoral or transradial access has reached diminishing returns. Fellows should understand that the true error in this scenario is not being aggressive but waiting too long before making the call.

BREATHE, YOU ARE IN THE ICA: NOW, WHAT TO DO WHEN EVT IS DIFFICULT?

Basic Rules

Before discussing specific tricks for the intracranial phase of the procedure, there are a few basic but fundamental rules that guide our practice:

Position Your Views Correctly

The anteroposterior projection should always focus on the intracranial circulation, while the lateral view must include the distal tip of the balloon guide or long sheath within the ICA. With this setup, the entire procedure, including balloon inflations, can usually be performed without moving the table. This simple habit saves time and reduces errors.

Shape Your Microwire Properly

In almost all cases (≈95%), the microwire tip should be shaped into a J. The J-tip serves 2 purposes: it naturally guides the wire toward the target occlusion, and it significantly reduces the risk of perforation. Other shapes are occasionally required, but they remain exceptions and will be discussed later.

Never Lose Your Access

Perhaps the most important rule: once you have access, keep it. Whether dealing with tandem lesions (atherosclerosis, dissection) or even a straightforward M1 occlusion, maintaining access is non-negotiable. This may mean advancing the long sheath slightly higher, leaving the aspiration catheter in place, or even keeping a microwire parked. Whatever the strategy, do not give up your access until the procedure is complete. Always.

Management of Difficult Siphon Anatomy

Play With Your Triaxial System

Some carotid siphons have unfavorable U- or V-shaped curves that limit the trackability of large-bore aspiration catheters, even with a standard coaxial setup (microcatheter and microwire). The first reflex is often to downsize the aspiration catheter. Although this may help, it is not always the best option when dealing with a large thrombus, where a bigger lumen is preferable. A second reflex is to increase the push on the aspiration catheter. Although this may also help, it is not the best strategy and may cause harm to the ophthalmic artery.

Our initial strategy is therefore to advance as far as possible with the J-shaped microwire and microcatheter. Whenever feasible, we favor catheterizing the inferior division of the middle cerebral artery, navigating into the angular branch, which is usually the largest branch of the middle cerebral artery territory.[31] Once this position is secured, we release tension on the system (see above for details) and attempt to track the aspiration catheter forward while slightly withdrawing the microcatheter and microwire (Figure 3C through 3E). This simple maneuver often allows the aspiration catheter to progress through the siphon: by releasing tension on the microwire and microcatheter, the system gains flexibility, and with a slight forward momentum, the aspiration catheter can be pushed a bit further upstream. If this fails, the next step is to switch to a stiffer microwire, such as the 200 cm Traxcess EX (Terumo), positioning the stiff segment at the ICA–middle cerebral artery junction. Importantly, the tip should remain in a J configuration to maintain safety.

Finally, if the aspiration catheter still cannot cross, we escalate to a stent-anchoring technique (within the thrombus), which provides additional support while limiting thrombus fragmentation.[28]

Stent-Anchoring Technique

This technique was first described in the context of giant aneurysm embolization, where looping a microcatheter inside the aneurysm allowed stent deployment to redirect the system into the arterial lumen.[28] The same principle can be applied to EVT. A stent retriever is partially unsheathed within the thrombus, and the aspiration catheter is then advanced over the stent pusher and microcatheter, using the radial force of the deployed stent as an anchor. A small, controlled pull on the stent pusher often improves the trackability of the aspiration catheter as it crosses the carotid siphon. Once the aspiration catheter has navigated beyond the tortuous segment, the microcatheter is removed, and continuous aspiration is applied just before reaching the thrombus. This approach is highly effective, but operators should be mindful of its economic implications: compared with a pure aspiration-first strategy (eg, ADAPT [A Direct Aspiration First Pass Technique]), it consumes an additional device. In some healthcare systems, this cost consideration may influence when and how often the stent-anchoring technique is used.

Downloaded from http://ahajournals.org by on March 15, 2026

Ledge or Stair-Step Effect at the Level of the Ophthalmic Artery: The Balloon-Tracking Technique

The ophthalmic artery often creates a ledge or stair-step effect, limiting downstream catheterization of the aspiration catheter.[32] This phenomenon explains why techniques such as SNAKE ([Sofia Non-Wire Advancement TechniKE]; navigating the aspiration catheter without a microcatheter or microwire) often fail, as the catheter tip gets trapped at the ophthalmic origin.[33] Sometimes this phenomenon is also present despite a triaxial system in place. The ledge effect is primarily due to a mismatch between coaxial catheters, when the inner lumen of the larger catheter does not match the profile of the smaller one, creating a step-off. The first way to mitigate this is simply to select catheters with coherent sizing, reducing the gap and minimizing the ledge. Before considering balloon-assisted tracking, several simpler maneuvers should always be attempted. Although this is not routinely practiced in our center, steam-shaping large-bore aspiration catheters into a gentle J configuration (as possible with the RED catheters [Penumbra]) can reduce the ledge effect created at the ophthalmic artery origin and often allows the system to track without additional devices. In addition, dedicated trackability-enhancing devices such as the Wedge microcatheter (Microvention) or the SENDit (Penumbra) may be used to facilitate advancement across challenging siphon angulations. Only when these preliminary approaches fail should balloon-assisted tracking be considered as a true second-line option for exceptionally resistant anatomies.

Borrowed from interventional cardiology, the balloon-tracking technique offers a solution.[34] A balloon is inflated at the tip of the aspiration catheter, which is then advanced as a unit. Inflation smooths out the mismatch, reducing the ledge and allowing the catheter to cross the siphon (Figure 4). Various balloons can be used, over-the-wire compliant or extracompliant (monolumen or dual-lumen), or rapid-exchange noncompliant types. That said, this is a second-line maneuver. We only resort to balloon tracking when simpler methods fail, because it requires additional devices, increases cost, and carries procedural risks. In most cases, the stent-anchoring technique suffices, as microcatheter and microwire advancement are not typically impeded by the ophthalmic origin. Balloon tracking should, therefore, be reserved for rare cases of extreme anatomy, where even stent deployment is unstable or unfeasible.

Shape Your Microwire to Save Some Time

As noted earlier, the J-shaped microwire is our default configuration in EVT. It provides both safety, by reducing perforation risk, and guidance toward the target occlusion. However, different shapes may be required depending on the vascular territory (Figure 5).

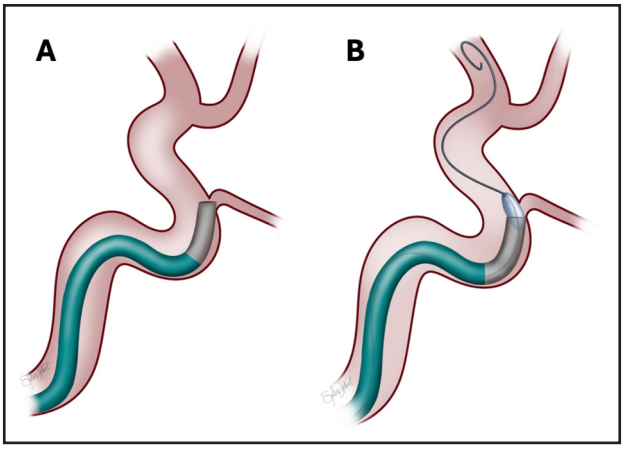

Figure 4. Balloon-tracking technique for carotid siphon navigation.
A, The ledge effect, in which the aspiration catheter cannot be advanced beyond the ophthalmic artery origin. **B**, Balloon-tracking technique, with balloon inflation at the tip of the aspiration catheter to overcome the ledge effect created by the ophthalmic ostium. The entire system is then advanced, after which the balloon is deflated and removed.

Double-Curved Microwire for Anterior Cerebral Artery Access

For catheterization of the anterior cerebral artery, particularly the A1 segment, we often use a double-curved microwire. This shape is the same as the one we routinely use for anterior communicating aneurysms. The technique is as follows: first, we introduce the microwire into the ICA (preshaped as a double-curved), where it naturally forms a J-shape as the tip is advanced against the petrous ICA junction. We then advance the J-shaped microwire into the middle cerebral artery, before gently withdrawing it while applying a slight counterclockwise torque. The wire often jumps naturally into the A1 segment. With careful torque, it can then be advanced into the A2 and A3 segments. Although fellows may hesitate to remove and reshape the wire, seeing it as a waste of time, experience shows that taking this step early often saves time overall.

Straight-Tip Microwire for Stenosis or Distal Occlusions

In cases of intracranial atherosclerotic stenosis or distal medium vessel occlusions, we sometimes prefer a straight tip. To keep this safe, we magnify the working view to monitor the wire's behavior carefully, advancing it only with very fine torque. If the tip moves freely (floppy), we continue pushing and torquing. The moment the tip appears caught in a small branch or against the vessel wall, we stop, withdraw slightly, and retry with extra torque and controlled advancement. Straight-tip shaping can be particularly useful for catheterizing difficult M2-M3 branches or negotiating tight stenoses. However, a J-shaped microwire should always be attempted first, with straight shaping reserved only for anatomies that remain inaccessible despite careful J-tip navigation.

Downloaded from http://ahajournals.org by on March 15, 2026

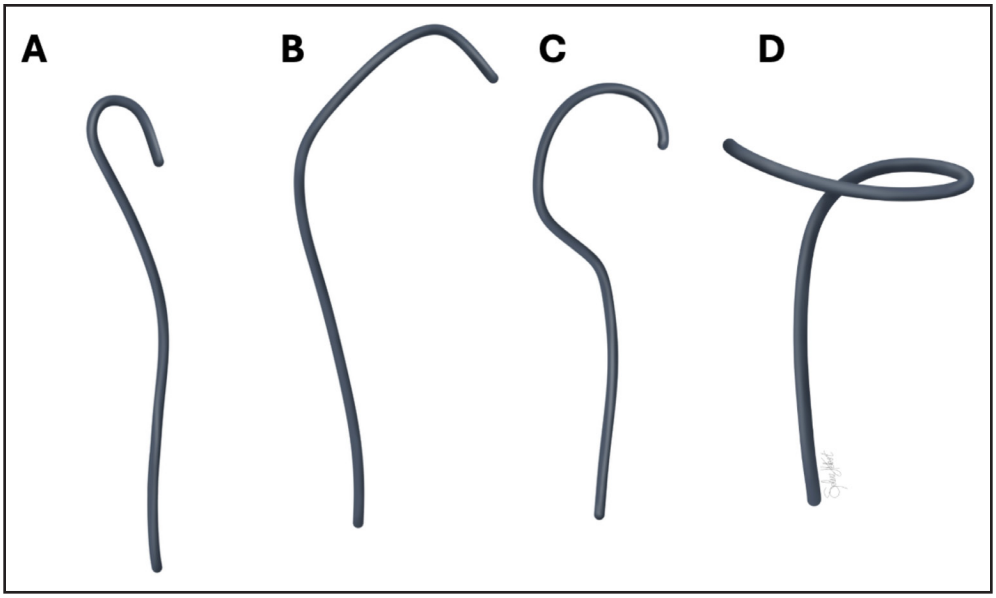

Figure 5. Different shapes of microwires used during neurointervention.
A, J-shaped microwire, commonly used during endovascular therapy to minimize the risk of arterial perforation. **B**, Double-curved microwire, particularly useful for anterior cerebral artery (ACA) catheterization. The tip is preshaped, the microwire advanced with a J-curve (formed in the petrous internal carotid artery [ICA]) into the middle cerebral artery, and then slowly withdrawn into the ICA while applying counterclockwise torque. This maneuver, combined with the preshaped tip, typically allows the wire to enter the A1 segment of the ACA, after which it is navigated distally. **C**, Spoon-shaped microwire, useful for middle meningeal artery catheterization. **D**, Pig-tail–shaped microwire, useful in challenging catheterization of carotid siphon aneurysms.

Ultimately, shaping the microwire is not wasted time; it is an investment. Fellows should understand that adapting the wire to the anatomy, rather than persisting with a suboptimal shape, often makes the difference between a smooth navigation and repeated failed attempts.

Tips and Tricks in Different Settings

Extreme Situation, Extreme Measures: Nanto Technique

In most centers, EVT is performed by a senior INR assisted by a fellow or resident. This makes complex maneuvers requiring 4 hands, such as intracranial or extracranial exchange maneuvers, more manageable. However, in some parts of the world, EVT may be performed by a single operator, making these exchanges particularly challenging. For example, crossing tandem lesions with dissection or intracranial stenosis may require the use of 300 cm exchange wires, difficult to handle alone.

For these rare situations, we teach our fellows the Nanto technique, which allows an exchange maneuver to be performed alone, without a dedicated exchange wire.[35] Although most commonly used to retrieve a microcatheter over a microwire, the principle can be adapted to an over-the-wire balloon, a rapid-exchange balloon, or even a diagnostic catheter, simply by adjusting the syringe size. The steps are straightforward. During an intracranial exchange, the microcatheter is withdrawn until its proximal hub contains the microwire tip. At this point, a 10 mL syringe filled with saline is attached firmly to the hub, with the microwire lying inside the syringe. The Y-connector of the guiding or aspiration catheter must be opened (critical, to avoid injecting the wire into the circulation). A strong saline injection is then delivered through the microcatheter. The hydraulic push generates enough force to withdraw the microcatheter while leaving the microwire perfectly stable in place. Once the microcatheter is completely out, the microwire can be locked and secured, allowing safe continuation of the procedure.

For detailed demonstrations, we refer the reader to the seminal publication and the teaching material from Professor René Chapot's Advanced Live Interventional Course of Essen.

Bilateral EVT: Cost or Efficiency?

Primary multivessel occlusions are rare (estimated at only 0.35% of cases in the series by Kaesmacher et al),[36] but in very high-volume centers (≥350–500 EVT per year), they are not exceptional and require a predefined strategy. Our approach is to use a parallel double setup, treating both large vessel occlusions simultaneously (Figure 6). We puncture both femoral arteries and place long sheaths into both ICAs. Work begins on the first occlusion, and while aspiration or a stent retriever is acting on that side (typically 3–4 minutes), we switch to the contralateral ICA. Devices are then retrieved alternately, allowing the procedure to continue seamlessly on both sides until reperfusion is achieved. This strategy clearly increases procedural cost (2 long sheaths, 2 aspiration catheters, 2 stent retrievers, but only 1 microcatheter).

Downloaded from http://ahajournals.org by on March 15, 2026

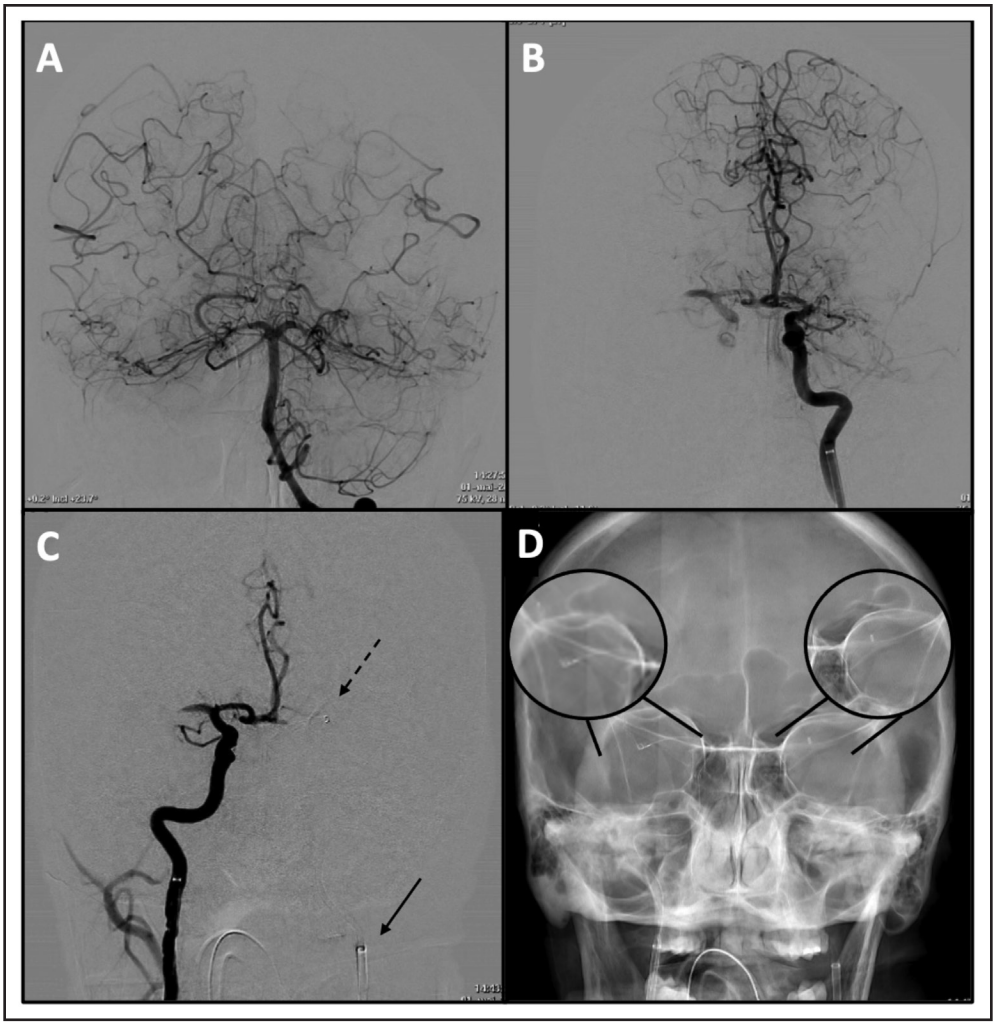

Figure 6. Simultaneous bilateral thrombectomy technique.
A, Left vertebral injection in anteroposterior projection demonstrating prominent bilateral leptomeningeal anastomoses, indirectly suggesting bilateral middle cerebral artery (MCA) occlusions. **B**, Left internal carotid artery (ICA) injection (anteroposterior) showing a proximal left M1 occlusion and a contralateral right M1 occlusion. **C**, Guiding catheter positioned in the left ICA (black arrow) and aspiration catheter under continuous suction in the left M1 segment (dashed arrow). While aspiration is maintained, a second guiding catheter is rapidly advanced into the right ICA. **D**, Combined thrombectomy on the right MCA using a Solitaire 4×20 mm stent retriever (Medtronic) with an aspiration catheter (Sofia 6, Microvention), while an additional Sofia 6 catheter is maintained on the left side before retrieval. Courtesy of Dr Simon Escalard.

Downloaded from http://ahajournals.org by on March 15, 2026

However, in selected patients, it can substantially shorten time metrics and maximize the chance of good outcomes. In other words, bilateral EVT is not just a technical trick, but a resource-intensive strategy that should be considered in centers with the experience, workflow, and volume to support it.

Impossible Tandem Dissection: Flossing Technique

Some tandem cervical dissections are almost impossible to cross: the guidewire systematically enters the false lumen of the ICA and cannot progress upstream. In these situations, patience is essential, trying different microwire tip shapes, switching diagnostic catheters, or attempting with a microcatheter. Yet, in certain cases, the lesion remains uncrossable.

When this occurs, we first assess the contralateral ICA and the vertebral artery to evaluate the circle of Willis. In select anatomies, the operator can then exploit collateral pathways using the flossing technique.[37] Originally developed by peripheral interventional radiologists, this method employs a retrograde approach and a snare to secure true lumen access.

Applied to EVT, the technique typically uses the posterior communicating artery (more often than the anterior, given its larger caliber and better angle) to reach the ICA retrogradely and ensure positioning in the true lumen (Figure 7). The steps are as follows:

1. We place a 0.014″ microwire in the proximal ICA just below the dissection, where antegrade crossing has failed (Figure 7A).
2. We then obtain a second access (femoral or radial) and advance a 6F long sheath into the vertebral artery.
3. We navigate a 0.021″ microcatheter (size depending on available snares) through the posterior

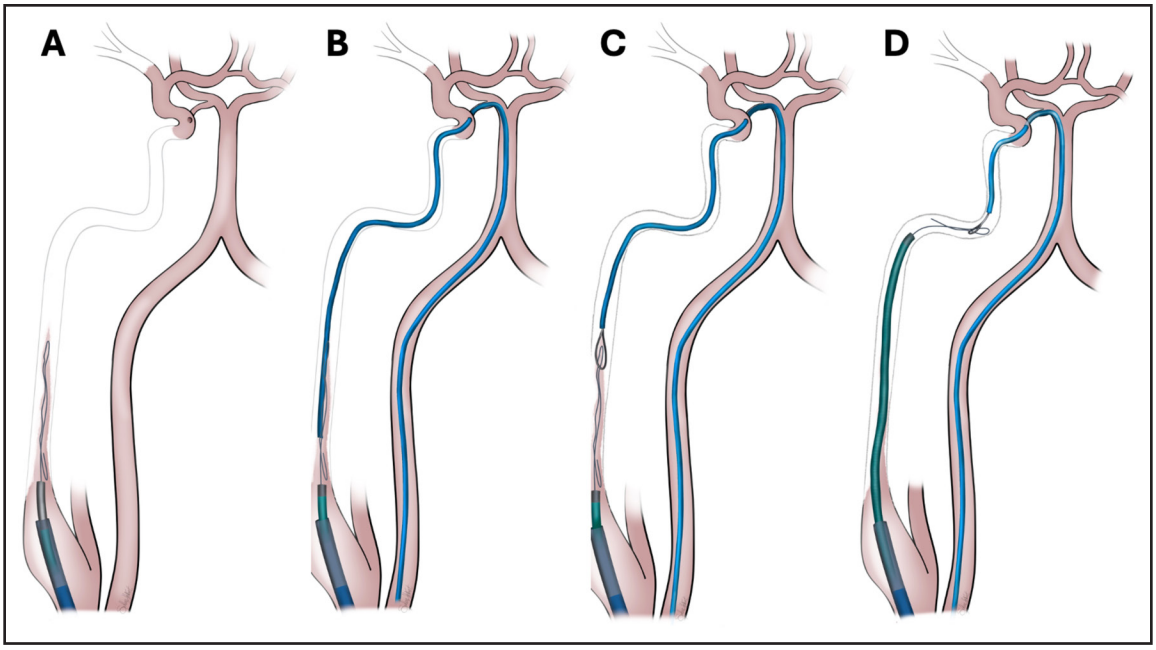

Figure 7. Flossing technique for difficult dissection catheterization.
A, Typical sus-bulbar right internal carotid artery (ICA) dissection with highly challenging catheterization of the true lumen. **B**, A 6F guiding catheter positioned in the vertebral artery (**right** or **left**), with a 0.021-inch microcatheter advanced through the right posterior communicating artery into the ICA, distal to the dissection. **C**, Deployment of a snare to capture the microwire or microcatheter proximal to the dissection. **D**, The snare is pulled into the true ICA lumen, allowing advancement of the triaxial system. If this maneuver fails, the microwire may be used to deliver a stent in the ICA.

communicating artery into the petrous or subpetrous ICA over a 0.014″ microwire (Figure 7B).

4. We deploy the snare distal to the dissection and advance it proximally through the occlusion, confirming true lumen passage.
5. We then capture the antegrade microwire with the snare and pull it retrogradely into the petrous ICA (Figure 7C).
6. We then advance the antegrade coaxial system over the wire into the true lumen, or alternatively, use the microwire itself to deploy a stent (monorail carotid stent if the vessel is straight, flow diverter in case of tortuosity due to dissection; Figure 7D).

This technique can also be applied in the posterior circulation, for example, by navigating from one vertebral artery into the other to straighten the vessel.

The flossing technique is a last-resort maneuver. It prolongs the procedure significantly and should only be attempted after conventional antegrade strategies have failed, because premature termination carries catastrophic outcomes.

DISCUSSION AND CONCLUSIONS

Generally speaking, the real challenge in INR is not handling easy cases, but mastering the skills needed to manage complications that arise in procedures initially considered easy. Every trainee, regardless of background, will eventually become competent in treating an M1 occlusion in a patient with straight supra-aortic vessels. But navigating tortuous supra-aortic access to reach the same M1 occlusion, extracting a resistant clot, or dealing with an iatrogenic M1 dissection requires a different level of expertise, one that can only be acquired through fellowship training. With EVT indications expanding and case volumes rising worldwide, the frequency of such complex scenarios will only increase.

Several studies have tried to estimate the number of EVT procedures required to achieve good outcomes, often suggesting a threshold of 30 to 50 cases for fellows before independent call duties.[38,39] We think this approach is misleading. A fellow who has performed 50, or even 70, straightforward EVT (easy arches, first-pass, or 2-pass reperfusions) may still be entirely unprepared for a complex supra-aortic catheterization or a technically demanding intracranial bailout. Instead of counting EVT procedures, we value the number and quality of diagnostic cerebral angiographies, particularly difficult ones requiring independent management of supra-aortic access. In our training model, after 200 to 300 cerebral angiographies, fellows transition to simulation-based teaching for intracranial maneuvers (coaxial systems, torque, stent deployment) using silicon-based arterial models.[40] They then move on to a small number of carefully selected easy EVT (about 10), followed quickly by exposure to a wide range of complex EVT cases where the full spectrum of tips and tricks can be learned. Once a fellow feels secure with complex diagnostic angiographies and

Downloaded from http://ahajournals.org by on March 15, 2026

complex EVT, even if their EVT count is only 20, they can, in our view, manage on-call cases with the same safety and confidence as senior staff. Ultimately, competence in INR is not defined by procedural numbers but by the ability to handle complex vascular anatomies and unexpected complications. Training pathways should therefore emphasize progressive exposure to challenging diagnostic angiographies, structured simulation, and graduated EVT experience. Looking ahead, the future of INR education will depend on frameworks that balance procedural volume with escalating complexity, ensuring that new interventionalists, whether trained in neurology, radiology, or neurosurgery, are not only proceduralists, but resilient problem-solvers capable of navigating the unexpected.

ARTICLE INFORMATION

Received October 29, 2025; final revision received December 4, 2025; accepted December 30, 2025.

Affiliations

Interventional Neuroradiology Department (B.M., S.H., S.E., H.R., J.-P.D., W.B., E.R., A.A.R., S.J.M., A.G., S.S., R.B., M.P., M.M.) and Biological Resource Center (J.-P.D., F.D., M.M.), Hôpital Fondation A. de Rothschild, Paris, France. Neurology Department, Hôpital Paris Saint-Joseph, France (B.M.). Université Paris Cité (B.M., J.-P.D., M.M.). Department of Neurology, Comprehensive Stroke Unit, Centre Hospitalier Universitaire (CHU) of Liège, Belgium (F.D.). GIGA Cardiovascular, University of Liège, Belgium (F.D.). Neurology Department, Hôpital Lariboisière, Paris, France (M.M.).

Acknowledgments

The authors gratefully acknowledge the contributions of >100 fellows from around the world (Japan, Poland, Saudi Arabia, Iran, Oman, Cote d'Ivoire, Niger, Portugal, Greece, Brazil, Israel, and many others) coming to our center over the years, whose presence has continuously challenged us, fostered humility, and enriched our pedagogical approach to interventional neuroradiology.

Sources of Funding

None.

Disclosures

None.

REFERENCES

1. Goyal M, Menon BK, van Zwam WH, Dippel DWJ, Mitchell PJ, Demchuk AM, Dávalos A, Majoie CBLM, van der Lugt A, de Miquel MA, et al; HERMES Collaborators. Endovascular thrombectomy after large-vessel ischaemic stroke: a meta-analysis of individual patient data from five randomised trials. *Lancet*. 2016;387:1723–1731. doi: 10.1016/S0140-6736(16)00163-X
2. Nogueira RG, Jovin TG, Liu X, Hu W, Langezaal LCM, Li C, Dai Q, Tao C, Mont'Alverne FJA, Ji X, et al; ATTENTION, BASICS, BAOCHE, and BEST Investigators. Endovascular therapy for acute vertebrobasilar occlusion (VERITAS): a systematic review and individual patient data meta-analysis. *Lancet*. 2025;405:61–69. doi: 10.1016/S0140-6736(24)01820-8
3. Huo X, Ma G, Tong X, Zhang X, Pan Y, Nguyen TN, Yuan G, Han H, Chen W, Wei M, et al; ANGEL-ASPECT Investigators. Trial of endovascular therapy for acute ischemic stroke with large infarct. *N Engl J Med*. 2023;388:1272–1283. doi: 10.1056/NEJMoa2213379
4. Yoshimura S, Sakai N, Yamagami H, Uchida K, Beppu M, Toyoda K, Matsumaru Y, Matsumoto Y, Kimura K, Takeuchi M, et al. Endovascular therapy for acute stroke with a large ischemic region. *N Engl J Med*. 2022;386:1303–1313. doi: 10.1056/NEJMoa2118191
5. Sarraj A, Hassan AE, Abraham MG, Ortega-Gutierrez S, Kasner SE, Hussain MS, Chen M, Blackburn S, Sitton CW, Churilov L, et al; SELECT2 Investigators. Trial of endovascular thrombectomy for large ischemic strokes. *N Engl J Med*. 2023;388:1259–1271. doi: 10.1056/NEJMoa2214403
6. Costalat V, Jovin TG, Albucher JF, Cognard C, Henon H, Nouri N, Gory B, Richard S, Marnat G, Sibon I, et al; LASTE Trial Investigators. Trial of thrombectomy for stroke with a large infarct of unrestricted size. *N Engl J Med*. 2024;390:1677–1689. doi: 10.1056/NEJMoa2314063
7. Writing Committee for the TI, Yoo AJ, Zaidat OO, et al. Thrombectomy for stroke with large infarct on noncontrast CT: the TESLA randomized clinical trial. *JAMA*. 2024;332:1355–1366. doi: 10.1001/jama.2024.13933
8. Bendszus M, Fiehler J, Subtil F, Bonekamp S, Aamodt AH, Fuentes B, Gizewski ER, Hill MD, Krajina A, Pierot L, et al; TENSION Investigators. Endovascular thrombectomy for acute ischaemic stroke with established large infarct: multicentre, open-label, randomised trial. *Lancet*. 2023;402:1753–1763. doi: 10.1016/S0140-6736(23)02032-9
9. Nogueira RG, Jadhav AP, Haussen DC, Bonafe A, Budzik RF, Bhuva P, Yavagal DR, Ribo M, Cognard C, Hanel RA, et al; DAWN Trial Investigators. Thrombectomy 6 to 24 hours after stroke with a mismatch between deficit and infarct. *N Engl J Med*. 2018;378:11–21. doi: 10.1056/NEJMoa1706442
10. Turc G, Bhogal P, Fischer U, Khatri P, Lobotesis K, Mazighi M, Schellinger PD, Toni D, de Vries J, White P, et al. European Stroke Organisation (ESO)–European Society for Minimally Invasive Neurological Therapy (ESMINT) guidelines on mechanical thrombectomy in acute ischemic stroke. *J Neurointerv Surg*. 2019;11:535. doi: 10.1136/neurintsurg-2018-014569
11. de Havenon A, Castonguay A, Nogueira R, Nguyen TN, English J, Satti SR, Veznedaroglu E, Saver JL, Mocco J, Khatri P, et al. Prestroke disability and outcome after thrombectomy for emergent anterior circulation large vessel occlusion stroke. *Neurology*. 2021;97:e1914–e1919. doi: 10.1212/WNL.0000000000012827
12. Drouard-de Rousiers E, Lucas L, Richard S, Consoli A, Mazighi M, Labreuche J, Kyheng M, Gory B, Dargazanli C, Arquizan C, et al; ETIS–Research Investigators. Impact of reperfusion for nonagenarians treated by mechanical thrombectomy: insights from the ETIS registry. *Stroke*. 2019;50:3164–3169. doi: 10.1161/STROKEAHA.119.026448
13. Dargazanli C, Fahed R, Blanc R, Gory B, Labreuche J, Duhamel A, Marnat G, Saleme S, Costalat V, Bracard S, et al; ASTER Trial Investigators. Modified thrombolysis in cerebral infarction 2C/thrombolysis in cerebral infarction 3 reperfusion should be the aim of mechanical thrombectomy: insights from the ASTER trial (Contact Aspiration Versus Stent Retriever for Successful Revascularization). *Stroke*. 2018;49:1189–1196. doi: 10.1161/STROKEAHA.118.020700
14. Lapergue B, Blanc R, Costalat V, Desal H, Saleme S, Spelle L, Marnat G, Shotar E, Eugene F, Mazighi M, et al; ASTER2 Trial Investigators. Effect of thrombectomy with combined contact aspiration and stent retriever vs stent retriever alone on revascularization in patients with acute ischemic stroke and large vessel occlusion: the ASTER2 randomized clinical trial. *JAMA*. 2021;326:1158–1169. doi: 10.1001/jama.2021.13827
15. Weschler PM, Leslie-Mazwi T, Mistry E. Endovascular thrombectomy in patients with preexisting disability: a review. *Stroke Vasc Interv Neurol*. 2024;4:e001326. doi: 10.1161/SVIN.124.001326
16. Sharashidze V, Nogueira RG, Al-Bayati AR, Grossberg JA, Haussen DC. Balloon anchoring technique for thrombectomy in hostile craniocervical arterial anatomy. *J Neurointerv Surg*. 2020;12:763–767. doi: 10.1136/neurintsurg-2019-015347
17. Chapot R, Stracke CP, Wallocha M, Rikhtegar R, Yamac E, Mosimann PJ. Bailout stentectomy of 47 self-expandable intracranial stents. *J Neurointerv Surg*. 2022;14:160–163. doi: 10.1136/neurintsurg-2021-017279
18. Chapot R, Nordmeyer H, Heddier M, Velasco A, Schooss P, Stauder M, Stracke P, Mosimann PJ. The sheeping technique or how to avoid exchange maneuvers. *Neuroradiology*. 2013;55:989–992. doi: 10.1007/s00234-013-1197-y
19. Munoz A, Jabre R, Orenday-Barraza JM, Eldin MS, Chen CJ, Al-Saiegh F, Abbas R, El Naamani K, Gooch MR, Jabbour PM, et al. A review of mechanical thrombectomy techniques for acute ischemic stroke. *Interv Neuroradiol*. 2023;29:450–458. doi: 10.1177/15910199221084481
20. Eltelbany M, Fabbri M, Batchelor WB, Cilia L, Ducoffe A, Endicott K, Epps K, McBurnie A, Neville R, Rosner C, et al. Best practices for vascular arterial access and closure: a contemporary guide for the cardiac catheterization laboratory. *Front Cardiovasc Med*. 2024;11:1349480. doi: 10.3389/fcvm.2024.1349480
21. Hernandez D, Requena M, Olive-Gadea M, de Dios M, Gramegna LL, Muchada M, García-Tornel A, Diana F, Rizzo F, Rivera E, et al. Radial versus femoral access for mechanical thrombectomy in patients with stroke: a noninferiority randomized clinical trial. *Stroke*. 2024;55:840–848. doi: 10.1161/STROKEAHA.124.046360
22. Siddiqui AH, Waqas M, Neumaier J, Zhang JF, Dossani RH, Cappuzzo JM, Van Coevering Iii RJ, Rai HH, Monteiro A, Sonig A, et al. Radial first or

Downloaded from http://ahajournals.org by on March 15, 2026

patient first: a case series and meta-analysis of transradial versus transfemoral access for acute ischemic stroke intervention. *J Neurointerv Surg*. 2021;13:687–692. doi: 10.1136/neurintsurg-2020-017225
23. Maier B, Finitsis S, Mazighi M, Lapergue B, Marnat G, Sibon I, Richard S, Viguier A, Cognard C, Gory B, et al. The benefit of a complete over a successful reperfusion decreases with time. *Ann Neurol*. 2023;93:934. doi: 10.1002/ana.26599
24. Burzotta F, Trani C, Mazzari MA, Mongiardo R, Rebuzzi AG, Buffon A, Niccoli G, Biondi-Zoccai G, Romagnoli E, Ramazzotti V, et al. Use of a second buddy wire during percutaneous coronary interventions: a simple solution for some challenging situations. *J Invasive Cardiol*. 2005;17:171–174.
25. Nishino K, Ito Y, Hasegawa H, Kikuchi B, Fujii Y, Tanaka R. Modified buddy wire technique for coil embolization of posterior circulation aneurysms. *Neuroradiology*. 2007;49:49–55. doi: 10.1007/s00234-006-0154-4
26. Kizilkilic O. Vertebral artery origin stenting with buddy wire technique in tortuous subclavian artery. *Eur J Radiol*. 2007;61:120–123. doi: 10.1016/j.ejrad.2006.08.023
27. Abdalkader M, Sahoo A, Lee J, Kiley N, Masoud HE, Norbash AM, Nguyen TN. Balloon gliding technique: a novel use of balloon guiding catheters in accessing challenging circulations when treating acute ischemic stroke. *Interv Neuroradiol*. 2023;29:196–200. doi: 10.1177/15910199221082473
28. Fargen KM, Velat GJ, Lawson MF, Hoh BL, Mocco J. The stent anchor technique for distal access through a large or giant aneurysm. *J Neurointerv Surg*. 2013;5:e24. doi: 10.1136/neurintsurg-2012-010276
29. Dumas V, Kaesmacher J, Ognard J, Forestier G, Dargazanli C, Janot K, Behme D, Shotar E, Chabert E, Velasco S, et al; JENI, SFNR and the YOUNICORN Research collaborations. Carotid artery direct access for mechanical thrombectomy: the Carotid Artery Puncture Evaluation (CARE) study. *J Neurointerv Surg*. 2022;14:1180–1185. doi: 10.1136/neurintsurg-2021-017935
30. Allard J, Ghazanfari S, Mahmoudi M, Labreuche J, Escalard S, Delvoye F, Ciccio G, Smajda S, Redjem H, Hebert S, et al. Rescue carotid puncture for ischemic stroke treated by endovascular therapy: a multicentric analysis and systematic review. *J Neurointerv Surg*. 2021;13:809–815. doi: 10.1136/neurintsurg-2020-016725
31. Shapiro M, Raz E, Nossek E, Chancellor B, Ishida K, Nelson PK. Neuroanatomy of the middle cerebral artery: implications for thrombectomy. *J Neurointerv Surg*. 2020;12:768–773. doi: 10.1136/neurintsurg-2019-015782
32. Kuriyama E, Matsuda Y, Kawaguchi T, Yako R, Nakao N. Analysis of the anatomical factors affecting ability to navigate penumbra catheter through internal carotid siphon. *J Neuroendovasc Ther*. 2020;14:169–176. doi: 10.5797/jnet.oa.2020-0003
33. Heit JJ, Wong JH, Mofaff AM, Telischak NA, Dodd RL, Marks MP, Do HM. Sofia intermediate catheter and the SNAKE technique: safety and efficacy of the Sofia catheter without guidewire or microcatheter construct. *J Neurointerv Surg*. 2018;10:401–406. doi: 10.1136/neurintsurg-2017-013256
34. Patel T, Shah S, Pancholy S. Balloon-assisted tracking of a guide catheter through difficult radial anatomy: a technical report. *Catheter Cardiovasc Interv*. 2013;81:E215–E218. doi: 10.1002/ccd.24504
35. Nanto S, Ohara T, Shimonagata T, Hori M, Kubori S. A technique for changing a PTCA balloon catheter over a regular-length guidewire. *Cathet Cardiovasc Diagn*. 1994;32:274–277. doi: 10.1002/ccd.1810320317
36. Kaesmacher J, Mosimann PJ, Giarrusso M, El-Koussy M, Zibold F, Piechowiak E, Dobrocky T, Meier R, Jung S, Bellwald S, et al. Multivessel occlusion in patients subjected to thrombectomy: prevalence, associated factors, and clinical implications. *Stroke*. 2018;49:1355–1362. doi: 10.1161/STROKEAHA.118.021276
37. Ogilvie ME, Tabibian BE, Harrigan MR. Flossing technique for endovascular repair of a penetrating cerebrovascular injury: illustrative case. *J Neurosurg Case Lessons*. 2022;4:CASE22225. doi: 10.3171/CASE22225
38. Cai Q, Zhu Y, Huang X, Xiao L, Gu M, Wang P, Zhang C, Chen J, Hu W, Wang G, et al. Learning curve for endovascular treatment of anterior circulation large vessel occlusion at a single center. *Front Neurol*. 2020;11:587409. doi: 10.3389/fneur.2020.587409
39. Liu C, Liu Y, Li Z, Gong P, Xu Z, Zhou J, Zhang W. Cumulative experience improves the procedures of mechanical thrombectomy. *BMC Neurol*. 2022;22:37. doi: 10.1186/s12883-022-02562-z
40. Freiherr von Seckendorff A, Delvoye F, Levant P, Solo Nomenjanahary M, Ollivier V, Bourrienne M-C, Di Meglio L, Piotin M, Escalard S, Maier B, et al. Modeling large vessel occlusion stroke for the evaluation of endovascular therapy according to thrombus composition. *Front Neurol*. 2021;12:815814. doi: 10.3389/fneur.2021.815814

Downloaded from http://ahajournals.org by on March 15, 2026